

**O.I. Arsenina,  
A.G. Nadtochiy,  
N. V. Popova**

Central Scientific Research Institute  
for Dentistry, Moscow  
St. Vladimir's Children's Clinical Hospital,  
No. 2, Moscow



O.I. Arsenina  
www.arsenina.ru

## STUDY OF THE ACT OF SUCKING IN HEALTHY BABIES IN BREAST- FEEDING AND ARTIFICIAL FEEDING USING NUK TEATS

The article will describe the advantage of NUK Silicone and Latex Teats for children of breastfeeding age. A comparative analysis has shown that when using NUK Teats, the act of sucking is physiological and fully imitates the act of sucking in breastfeeding.

Key words: *act of sucking, artificial feeding, NUK Teat.*

The aim of the research is to evaluate the quality of the act of sucking in healthy babies in artificial feeding using NUK Teats (Germany).

### Research material and methods

The act of sucking was studied in 60 babies (23 boys and 37 girls) aged from 7 days to 6 months. There were 30 babies in the breast feeding group. They constituted the first group. The second group also comprised 30 babies, who received expressed breast milk from NUK Teats. The examinations were carried out at intervals with the child at 1 month (twice), at 1.5 months, at 3 months and at 6 months.

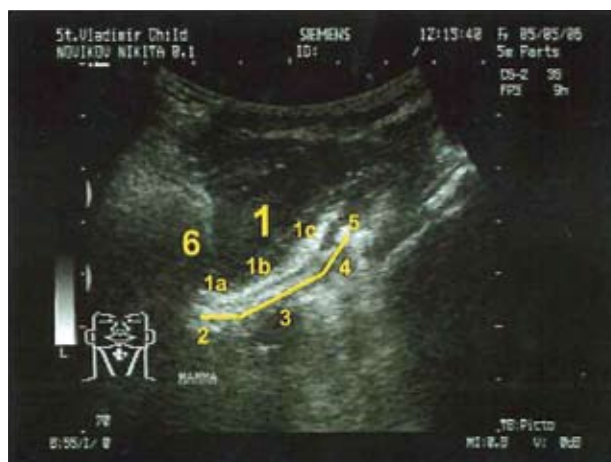
An ultrasound examination was performed using the "Sonoline Sienna" system (made by Siemens) with a convex sensor (3.5 – 5.0 MHz).

The physiology of sucking and the ingestion of milk were evaluated according to the position of the tongue and the coordination of the movement of its anatomical parts (the tip, the back, the root), the speed and rhythm of the movement of the tongue, the movements of the soft palate. In addition, the number of sucking movements and feeding time were taken into consideration and also the position of the mother's nipple and the tip of the nipple in the child's mouth cavity.

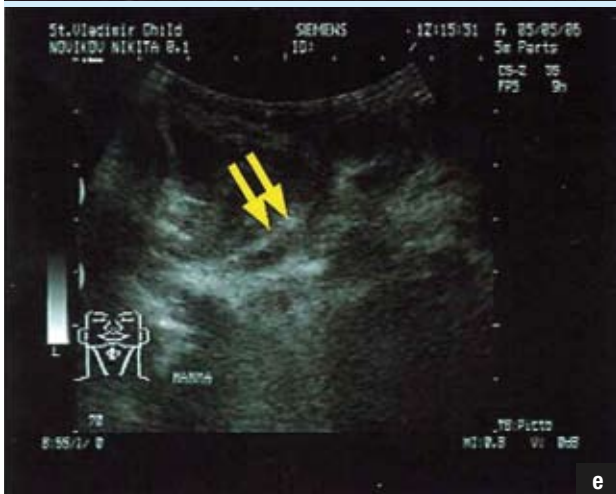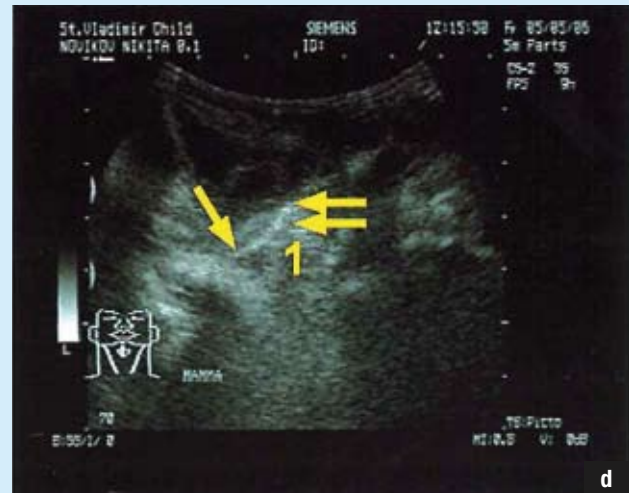
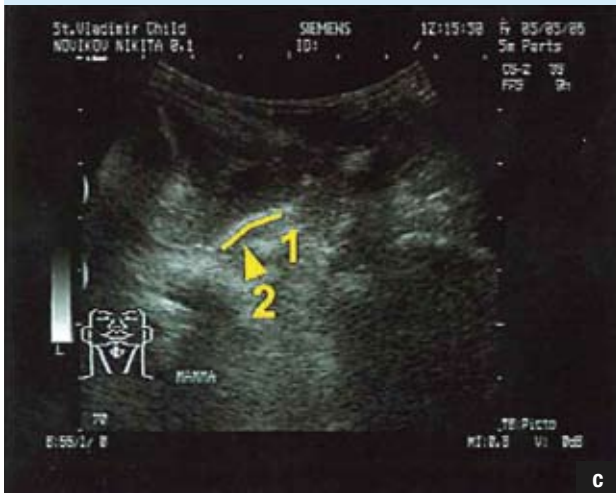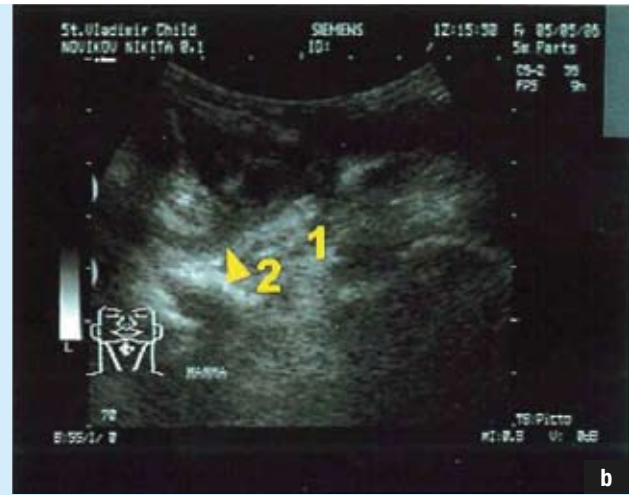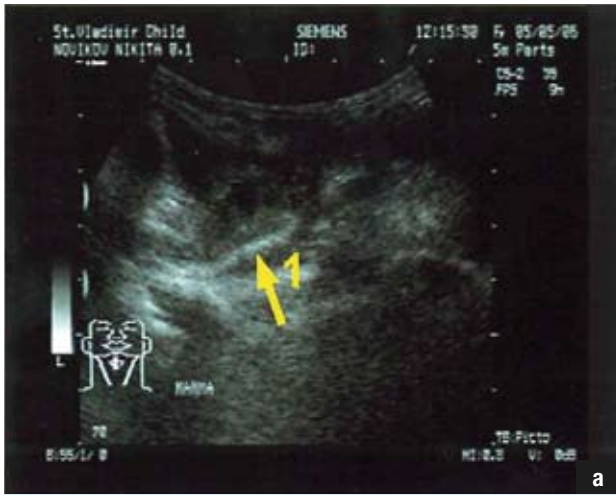An ultrasound scan is the most informative, non-invasive and safe method for studying the physiology of sucking and swallowing as far as the baby is concerned. The sonogram visualised all sections of the tongue, the premaxillary bone, the hard and the soft palate (Figures 1 – 3) clearly. The sonogram examination enabled us to visualise the movements of the soft tissue structures during sucking and ingestion.

Physiologically, the sucking process has three successive stages, characterised by the harmonious movements of the back and the root of the tongue and the soft palate, which ensure that the milk enters the oral cavity and the oral pharynx.

In the first stage, the tip of the tongue lowers, enveloping the nipple from the bottom and pressing it against the hard palate, whereupon the lips press against the nipple area of the milk gland, ensuring the closure of the oral cavity space.



**Fig. 1.** Normal anatomy of the oral cavity; sagittal plane. 1 – Tongue: 1a – Tip of the tongue, 1b – Back of the tongue, 1c – Root of the tongue; 2 – Premaxillary bone; 3 – Hard palate; 4 – Soft palate; 5 – Oral pharynx; 6 – Lower incisors.



**Fig. 2.** The dynamics of the act of sucking in breastfeeding: **a** – The back of the tongue starts to move downwards (indicated by the arrow), forming a rarefied space in the oral cavity (1); **b** – The back of the tongue continues in its movement downwards (indicated by the arrow), increasing the size of the space in the oral cavity (1), into which the milk starts to flow (2); **c** – The back of the tongue reaches its lowest position (indicated by the arrow), the space in the oral cavity reaches its maximum size (1) and fills with milk (2); **d** – The back of the tongue rises, returning to its original position (indicated by the arrow), but the root of the tongue moves forward (indicated by the two arrows). The milk flows into the oral pharynx (1); **e** – The back of the tongue remains in the previous position (indicated by the arrow), but the root of the tongue moves backwards to its original position (indicated by the two arrows). The milk flows out of the oral pharynx into the oesophagus.

At this stage, the back of the tongue is located high up, reaching the hard and the soft palates.

In the second stage, the back of the tongue lowers which creates a rarefied space in the oral cavity and ensures that the milk from the nipple enters the oral cavity (Fig. 2, a-c). The position of the root of the tongue does not change whilst this is going on.

The third stage of sucking is characterised by the combined movement of the back of the tongue upwards and the root of the tongue forward, thanks to which the milk flows from the oral cavity into both the oral pharynx and on into the oesophagus (Fig. 2, d, e).



**Fig. 3.** Ultrasound examination.



**Fig. 4.** NUK Teat: **a** – External view; **b** – Physiological shape of the teat: 1 – The highly convex upper part helps the development of the palate and the jaw; 2 – The hole in the upper part of the rubber teat is deliberately retroverted a little. Such a position ensures that the drink goes to the right place. This is one of the most important factors to promote good digestion; 3 – The valve prevents air being swallowed during sucking and the baby feels more comfortable; 4 – The tongue presses against the specially flattened lower rubber part of the teat, where it is much wider. This promotes the growth of the lower jaw.

In the scope of the experiment the biomechanical act of sucking when using NUK Teats with an aerosystem was studied (Figs. 4, 5). The accentuated flat base of the teat fits tightly against the upper lip – this develops the “milking” movements of the lower jaw. The concave lower part of the teat helps the baby to push the lower jaw forward when it drinks.

When using NUK Teats with an aerosystem, the movements of the tongue corresponded with the phasic nature of the act of sucking and swallowing with in breastfeeding (Fig. 5). The same type of sucking was recorded in both groups of those examined. This proves that this design of teat promotes a physiological type of sucking.

### Conclusion

The same type of sucking was recorded in both groups. This shows that the design of the NUK Teat promotes a physiological type of sucking.

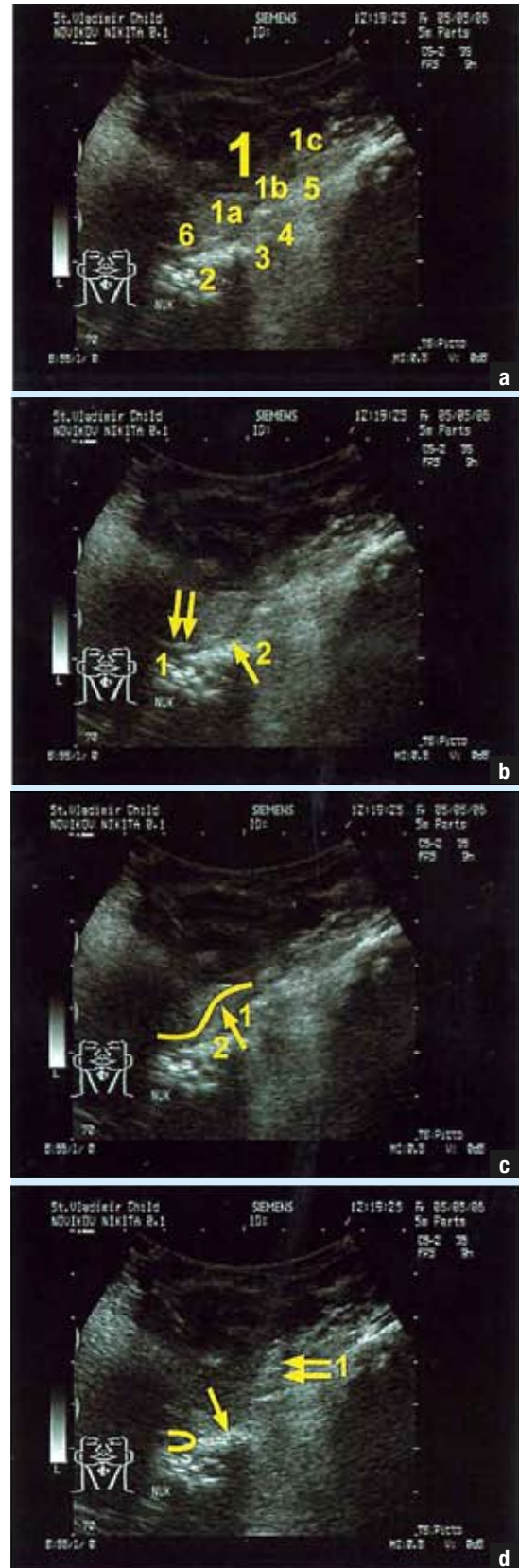
### Summary

#### EVALUATION OF SUCKING IN HEALTHY INFANTS IN BREASTFEEDING AND ARTIFICIAL FEEDING WITH NUK TEATS

Prof. Arsenina O.I. Nadtochiy A.G., Popova N.V.

In the article the advantages of the use of NUK Teats in infants are described. Comparative analysis has shown that on application of NUK Teats sucking was physiological and fully imitated sucking in the breastfeeding.

Key words: *teats, report of sucking.*



**Fig. 5.** The dynamics of the act of sucking when using NUK Teats: **a** – Anatomy of the oral cavity: 1 – Tongue: 1a – top of the tongue, 1b – Back of the tongue, 1c – Root of the tongue; 2 – Premaxillary bone, 3 – Hard palate, 4 – Soft palate, 5 – Oral pharynx, 6 – Tip of NUK Teat; **b** – Tip of the tongue moves upwards (indicated by the two arrows), pressing down on the tip of the NUK Teat (1). The back of the tongue starts to move downwards (indicated by the arrow), forming a rarefied space in the oral cavity (2); **c** – The back of the tongue takes up its lowest position (indicated by the arrow), the space in the oral cavity reaches its maximum size (1) and fills with milk (2); **d** – The back of the tongue goes up returning to its original position (indicated by the arrow), but the root of the tongue moves forward (indicated by the two arrows). The milk enters into the oral pharynx (1).